



Patient Name: UniPath, Sample Derm

Accession Number: T88-000119

Patient ID: 1122152

Birth Date: 1/1/1901 Age: 103

Date Obtained: 1/7/2004

Sex: Female

Date Received: 1/7/2004

Clinician: UniPath Referring Physician \* 123 Main St \* Denver, CO 80022 303-512-0888

**Site(s) of Biopsy:**

Skin Right Nose, Shave Biopsy

**Pertinent History:**

None provided.; Medical Record Number: MRN1234

**Final Pathologic Diagnosis:**

**SKIN, RIGHT NOSE, SHAVE BIOPSY:  
-- BASAL CELL CARCINOMA, NODULAR TYPE,  
EXTENDING TO THE DEEP MARGIN. TKW/**

**\* Electronically Verified \***

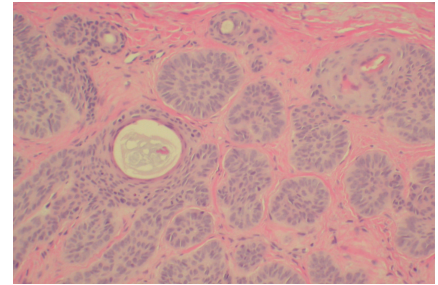
Traci Weyand  
IT Manager  
01/07/2004

**Microscopic Examination and Description:**

The dermis is infiltrated by nests of atypical basaloid cells, which show peripheral palisading and are associated with fibromyxoid stroma from which they are separated by clefts. Both mitotic figures and necrotic cells are identified and necrotic cells are present. TKW/

**Gross Examination and Description:**

Received in formalin in one container labeled "UniPath, Sample Derm" and "right nose" is a gray-tan shave biopsy, 0.5 x 0.3 x 0.1 cm. The surgical margin is inked. The specimen is bisected and submitted entirely in one cassette. TKW/



Right nose