



Patient Name: UniPath, Test 12082004

Accession Number: N88-000001

Patient ID: 1153826

Birth Date: 1/1/1901 Age: 103

Date Obtained: 12/22/2004

Sex: Female

Date Received: 12/22/2004

Clinician: UniPath Referring Physician * 123 Main St * Denver, CO 80022 303-512-0888

Specimen Description:

A. FNA, Right Thyroid; B. FNA, Left Thyroid

Pertinent History:

None Provided; Medical Record Number: 1234

Cytologic Interpretation:

- A. RIGHT THYROID NODULE FINE NEEDLE ASPIRATION:
-- CYTOLOGIC CHANGES CONSISTENT WITH ADENOMATOID NODULE.
- B. LEFT THYROID NODULE FINE NEEDLE ASPIRATION:
-- CYTOLOGIC CHANGES CONSISTENT WITH ADENOMATOID NODULE. MGV/tkw

* Electronically Verified *

Michael G. Venrick, M.D.
Pathologist
12/23/2004

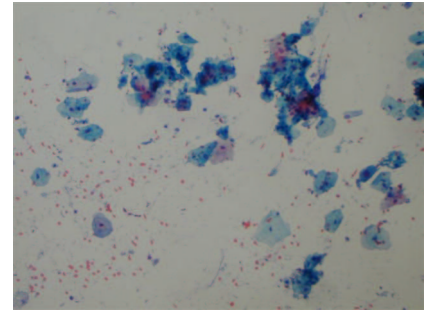
Microscopic Examination and Description:

- A. Right thyroid aspiration shows representative material to be present as follows:
 1. Cohesive groups of cytologically benign follicular cells are present. Some have Hurthle cell change. No cytologic changes worrisome for a malignancy were identified.
 2. Abundant free colloid is present.
 3. The background is blood.
- B. Review of the stained slides show cytologic changes similar to those described in specimen A. and will not be described further.
MGV/tkw

Gross Examination and Description:

This 48 year old female has had a rather extensive work-up for a visible and palpable thyroid nodule with a request for a fine needle aspiration. The clinical history is that of a visible and palpable right lower lobe nodule and a smaller non-visible nodule by ultrasound on the left side.

A disclosure consent form was obtained.



A. Right Thyroid Nodule: You are correct this is a Pap.

Patient Name: **UniPath, Test 12082004**

Accession Number: **N88-000001**

Birth Date: 1/1/1901 Age: 103

Date Obtained: 12/22/2004

Sex: Female

Date Received: 12/22/2004

Physical examination limited to the neck revealed a visible and palpable thyroid nodule, right lower lobe. It is approximately 3-4 cm. It is movable. A palpable nodule in the left lower lobe is identified at approximately 0.5-1.0 cm. It is freely movable. No other nodules are noted. No cervical lymphadenopathy was palpated.

- A. Right Thyroid Fine Needle Aspiration received is 30 cc Pink fluid. Processed and stained are 1 monolayer and 5 direct smears.

Immediate evaluation for adequacy: Representative thyroid material present.

- B. Left Thyroid Fine Needle Aspiration received is 30 cc pink fluid. Processed and stained are 1 monolayer and 5 direct smears.

Immediate evaluation for adequacy: Representative parenchymal material present. MGV/tkw